



## PATIENT

Sasquatch Sadahiro

## SPECIES

Feline

## BREED

Sphynx

## SEX

Male Neutered

## AGE

8 years

## WEIGHT

7.6lbs

## INTERPRETED BY

Maggie Machen Lamy,  
DVM, DACVIM  
(Cardiology)

## IMAGING PERFORMED BY

Jessican Bailes, DVM

## HOSPITAL NAME

All Creatures Great &  
Small Veterinary Clinic

## REFERRING VET

Dr. Sadahiro

## INVOICE

45853

## DATE

11/20/25

## PRESENTING CLINICAL SIGNS

History: Grade 2-3/6 heart murmur. Asymptomatic. Some weight loss. Asthma; rarely given Albuterol.  
-Abnormal lab results: CBC: WNL CHEM: 0.6mg/dl Creat, otherwise NSF. Pro-BNP 37pmol/L T4: WNL @2.6ug/dL FELV/FIV NEG/NEG.

## ECHOCARDIOGRAM FINDINGS

2D, m-mode, color flow and doppler imaging is available. The left ventricular wall is largely normal with regions of borderline hypertrophy. There is a mildly hyperechoic endocardium consistent with fibrosis and remodeling. The endocardium also appears remodeled. The MV appears thickened. A mild LVOTO is appreciated on multimodal imaging, although not captured on spectral doppler. Mild MR. The left atrium is normal in size. The right atrium is normal in size. The right ventricle appears normal. Blood flow through the RVOT is mildly elevated in velocity with a dynamic profile. No obvious TR. There is no pleural or pericardial effusion seen. There are no obvious cardiac tumors.

## CARDIAC CHART

FELINE CARDIAC PARAMETERS	BODY WEIGHT (kg)	HR (BPM)	IVSd (cm) <small>(Moise, Pipers)</small>	LVIDd (cm) <small>(Moise, Pipers)</small>	LVWd (cm) <small>(Moise, Pipers)</small>	FS (%)	EF (%)
NORMAL PARAMETER	-----	150-240	0.35-0.55	<2 (mean 1.5)	3.5-0.55	35-67	80-100
PATIENT	3.4	NM	0.53	1.1	0.51	66	95
FELINE CARDIAC PARAMETERS	LA/AO <small>(Boon)</small>	LA/AO HEART BASE (Swe) <small>(Abbott)</small>	LA 2D short axis Base view (cm) <small>(Abbott)</small>		LVOT VEL <small>(m/s)</small>	RVOT VEL <small>(m/s)</small>	E max <small>(m/s)</small>
NORMAL	<1.5	<1.3	<1.2		<1.6	<1.3	<0.9
PATIENT	NM	1.2	1.2		1.5	1.8	NM
<p><i>*Note: All measurements based upon multi-modal images and methods. An average value is reported.</i> Adapted from June Boon, Veterinary Echocardiography, 1998 Abbott J &amp; MacLean H JVIM 2006;20: 111-119, Moise et al. Am J Vet Res 47:1476, 1986. Pipers et al. Am J Vet Res 40:882, 1979.</p>							

## INTERPRETATION OF THE FINDINGS & FURTHER RECOMMENDATIONS

Mild abnormalities are identified. The murmur is due to an intermittent LVOT obstruction at elevated heart rates. There are also borderline LV wall dimensions, in addition to mild remodeling and fibrosis of the left ventricular wall. These changes may be indicative of early cardiac disease (HOCM) or may simply represent a normal variant. Serial echocardiography will be necessary to determine progression and clinical relevance of both findings in this cat. Additionally, a dynamic RVOT obstruction is noted, which is a benign flow abnormality which may contribute to murmur intensity.

In patients with persistent LVOT obstruction and an elevated pressure gradient, a beta blocker is often prescribed to lower heart rate and decrease the gradient. In this patient with a mild obstruction and borderline normal LA/LV dimensions, no medications are clearly indicated.

From a structural standpoint, anesthetic risk is currently low. Avoid heart rate stimulating drugs (atropine, glycopyrrolate) unless clinically necessary. Avoid vasodilators such as acepromazine as



## PATIENT

Sasquatch Sadahiro

## SPECIES

Feline

## BREED

Sphynx

## SEX

Male Neutered

## AGE

8 years

## WEIGHT

7.6lbs

## INTERPRETED BY

Maggie Machen Lamy,  
DVM, DACVIM  
(Cardiology)

## IMAGING PERFORMED BY

Jessican Bailes, DVM

## HOSPITAL NAME

All Creatures Great &  
Small Veterinary Clinic

## REFERRING VET

Dr. Sadahiro

## INVOICE

45853

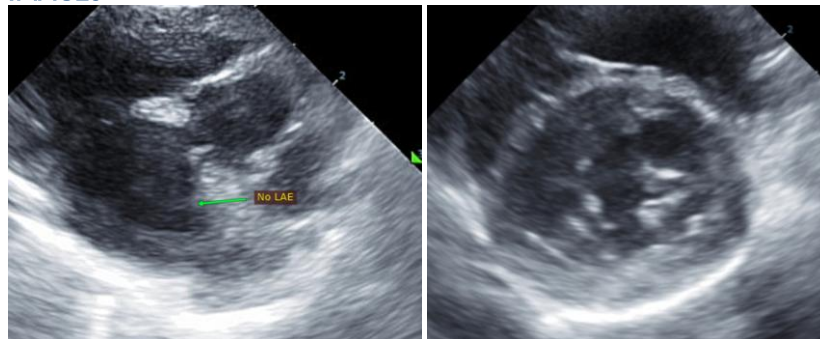
## DATE

11/20/25

this can worsen obstruction. Judicious IV fluid rates are recommended to avoid fluid overload in this patient with diastolic dysfunction.

A recheck echocardiogram is recommended in 6-12 months, sooner if any clinical signs arise.

## IMAGES



The information and recommendations provided are based on the images presented by the referring veterinarian. No evaluation can be communicated regarding pathology that was not visible in the image/video clips provided.

Thank you for this referral. This report was generated using transcription software, and minor dictation errors may be present. If the clinical or image interpretation does not parallel your findings or if I can be of any further assistance, please contact me.

**Maggie Machen Lamy, DVM**  
**Diplomate of the American College of Veterinary Internal Medicine (Cardiology)**  
info@sonopath.com